



## Tuberculosis of the thoracic spine

### A CLASSIFICATION BASED ON THE SELECTION OF SURGICAL STRATEGIES

J. S. Mehta, S. Y. Bhojraj

From Hinduja Hospital, Mahim Mumbai, India

**I**n spinal tuberculosis MRI can clearly demonstrate combinations of anterior and posterior lesions as well as pedicular involvement. We propose a classification system, using information provided by MRI, to help to plan the appropriate surgical treatment for patients with thoracic spinal tuberculosis. We describe a series of 47 patients, divided into four groups, based on the surgical protocol used in the management. Group A consisted of patients with anterior lesions which were stable with no kyphotic deformity, and were treated with anterior debridement and strut grafting. Group B comprised patients with global lesions, kyphosis and instability who were treated with posterior instrumentation using a closed-loop rectangle with sublaminar wires, and by anterior strut grafting. Group C were patients with anterior or global lesions as in the previous groups, but who were at a high risk for transthoracic surgery because of medical and possible anaesthetic complications. These patients had a global decompression of the cord posteriorly, the anterior portion of the cord being approached through a transpedicular route. Posterior instrumentation was with a closed-loop rectangle held by sublaminar wires. Group D comprised patients with isolated posterior lesions which required posterior decompression only.

**An understanding of the extent of vertebral destruction can be obtained from MRI studies. This information can be used to plan appropriate surgery.**

*J Bone Joint Surg [Br] 2001;83-B:859-63.*

*Received 14 March 2000; Accepted after revision 8 March 2001*

J. S. Mehta, MS Orth, D Orth, MCh Orth, Orthopaedic Specialist Registrar  
Kent and Sussex Hospital, Mt Ephraim, Tunbridge Wells TN9 8AT, UK.

S. Y. Bhojraj, MS Orth, Consultant Spinal Surgeon  
Hinduja Hospital, Veer Sauarkar Marg, Mahim Mumbai 16, India.

Correspondence should be sent to Dr J. S. Mehta at 13 Whitehaven Close, Bromley, Kent BR2 0YA, UK.

©2001 British Editorial Society of Bone and Joint Surgery  
0301-620X/01/611142 \$2.00

Tuberculosis causes three million deaths each year, and 90 million new cases have been diagnosed in the last ten years.<sup>1-3</sup> Vertebral disease is the commonest form of skeletal tuberculosis, accounting for half of the cases.<sup>3</sup> The most frequent sites of involvement are the thoracic and the thoracolumbar spine.<sup>4-8</sup> Multilevel disease is common and the incidence of skip lesions is reported as between 7% and 10%.<sup>3,9,10</sup> The role of plain radiography in diagnosing this condition remains predominant although the introduction of CT and MRI have added a new dimension to understanding the pathology.<sup>3,4,10-14</sup> The incidence of combined anterior and posterior involvement is greater than has been considered on the basis of radiographs alone. These combined lesions can compromise stability.

Adjustment of the level of aggression in the surgical management of these lesions, according to the extent of the disease, leads to improvement in outcome. We present a classification based on the selection of the appropriate surgical management.

### Patients and Methods

Between May 1993 and July 1998, 47 patients had surgical treatment by the senior author (SYB) for tuberculous spondylodiscitis of the thoracic and thoracolumbar spine. The diagnosis was based on clinical and radiological evaluation. Additional imaging, in the form of CT or MRI, was used to ascertain the extent of the lesion, the site and degree of compression of the cord, the status of the cord and the presence of skip lesions. A definitive diagnosis was made after histological examination of tissue removed at surgery. All patients had 'active' lesions. Those with reactivation of disease, old healed lesions with residual deformity or a late-onset neurological deficit were excluded.

All received antituberculous chemotherapy starting two weeks before surgery. Pyrazinamide was given for the first four months only. Treatment with ethambutol, rifampicin, isonicotinic acid hydrazide and folic acid supplement continued for a year. Patients with resistant atypical mycobacterial strains were treated on the basis of microbiological advice, the reserve drugs being kanamycin and ciprofloxacin.

The patients were placed in four groups, based on the extent of the lesion and patient-related risk factors. The

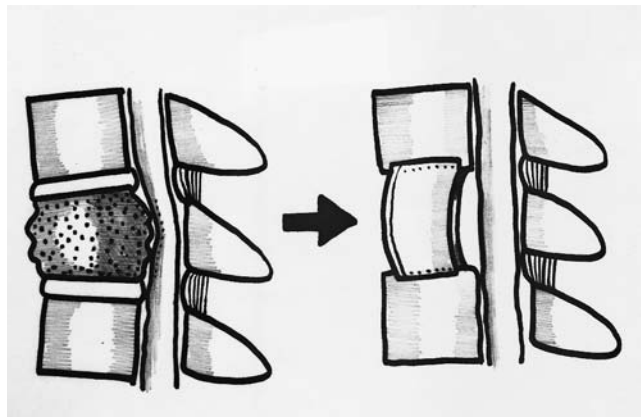


Fig. 1a

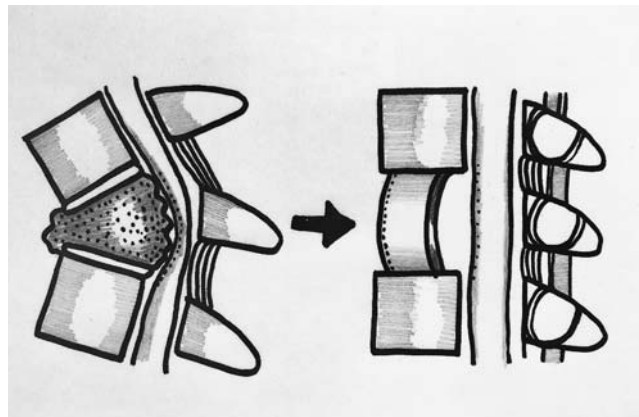


Fig. 1b

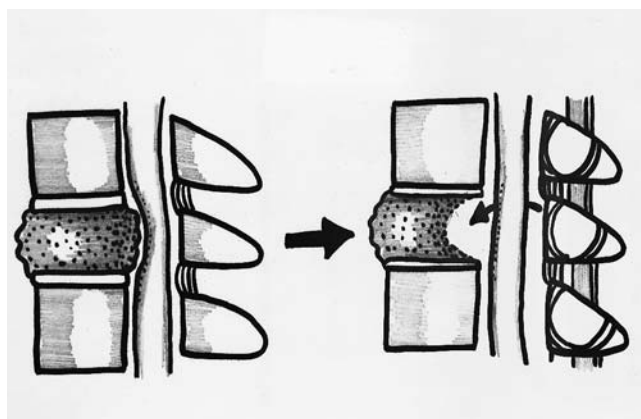


Fig. 1c

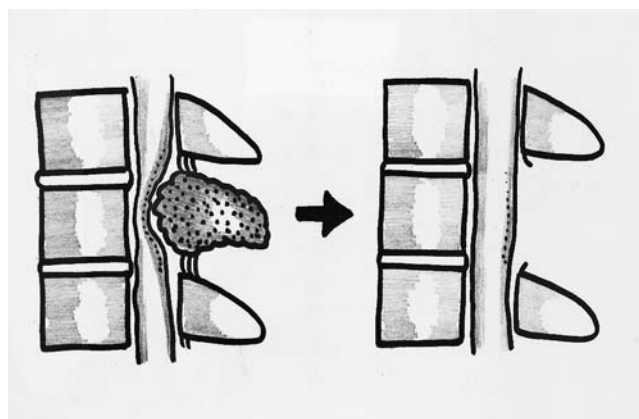


Fig. 1d

Diagrams showing the lesions associated with tuberculosis of the thoracic spine in a) group A, b) group B, c) group C and d) group D.

Frankel grading system was used to document abnormal neurological findings with specific attention being given to walking ability, sphincter involvement and the level of the lesion. After operation the patients were mobilised using a thoracolumbar orthosis. The neurological status determined the degree of mobilisation. The orthoses were discarded after clinical and radiological evidence of a sound fusion had been obtained.

## Results

**Group A.** This group comprised 12 patients (10 women and 2 men) with a mean age of 35.33 years (17 to 49). The lesion was limited to the anterior column, with no abnormal signals on MRI at, or posterior to, the pedicles. No deformity was present. The lesion was either paradiscal or central body in type<sup>3,10</sup> (Fig. 1a).

Transthoracic debridement and decompression of the cord were carried out with the introduction of a strut graft across the defect. Five patients had a lesion at a single level, five at two levels and two had involvement at more than three levels.

The mean follow-up was for 29 months (7 to 55). Seven

patients had no neurological deficit before or after surgery. They had an operation because they had severe pain which did not respond to conservative management. Of those with abnormal neurological signs, three who had been graded as Frankel C before operation, recovered completely and two had persistent spasticity.

**Group B.** Of the 16 patients in this group, 11 were women. The mean age at presentation was 31.3 years (18 to 55). The lesions involved the anterior and posterior columns at the same levels and were unstable with an associated kyphosis (Fig. 1b). A two-stage operation was carried out with posterior instrumentation using a closed-loop rectangle and sublaminar wires spanning at least three levels on either side of the lesion, followed by anterior decompression and strut grafting. Nine patients had lesions at two levels and four had involvement of more than three. The three patients with single-level disease in the upper thoracic spine, were fused at three levels above and below the lesion.

The mean follow-up was for 34 months (6 to 60). All had some neurological deficit before operation but 14 had improved, returning to predisease function. One patient with a complete paraplegia before operation showed no

recovery. One deteriorated initially because of chest complications and a brain tuberculoma, but recovered partially thereafter. Spinal contours were well maintained at the final follow-up.

**Group C.** This group comprised 13 patients (6 women and 7 men) with a mean age of 67 years (44 to 70). The lesion was either widespread, as in group B, or anterior, as in group A, but these patients were unwell, infirm or elderly, and it was felt that surgery involving thoracotomy would subject them to a high anaesthetic risk, with a potential for postoperative chest complications (Fig. 1c). A posterior transpedicular route was used to decompress the cord with a spinal nerve at the level of the foraminotomy being sacrificed to obtain better access. This did not cause additional morbidity. The spine was stabilised using a closed-loop rectangle fixed by sublaminar wires. Anterior grafts were not used. Of these patients, 11 had a lesion at two levels, one at a single level and one at three levels.

The mean follow-up was for 35 months (6 to 61). All had had abnormal neurological signs on presentation. Ten had a full recovery and two had improvement but had diminution of power (Frankel C) in the lower limbs at final follow-up. One patient did not recover despite decompression, possibly because of irreversible pathological damage to the spinal cord.

**Group D.** There were six patients in this group (2 women and 4 men) with a mean age of 47 years (31 to 67). The lesion involved the posterior elements with no associated instability or deformity (Fig. 1d). A limited decompression was undertaken using a posterior approach, the extent of which was dictated by the amount of local destruction. There was no instrumentation or fusion. Some lesions were granular and dry, forming a thick cuff of tissue around the cord. Excision of this tissue represented the decompression. Five of the patients had involvement of three levels.

The mean follow-up was for 31 months (17 to 44). Before operation, all the patients had a neurological defect; all improved after surgery.

## Discussion

Improved technology in the field of imaging has added a new dimension to the understanding of the surgical pathology of spinal tuberculosis.<sup>3,4,10-14</sup> Recent studies indicate that simultaneous involvement of the anterior and posterior columns is more common than has been previously considered. A lesion involving both columns compromises stability.<sup>1,4,15-22</sup> Involvement of the pedicle and facets are important factors in the genesis of instability, particularly if combined with destruction of a vertebral body at the same level.

Before MRI, the preoperative assessment of the extent of a lesion was by plain radiography. Since at least 30% to 40% of the bone mineral has to be lost for an abnormality to be detected radiologically early lesions can be missed if radiography alone is relied on. It has been reported that the

long-term outcome of the deformity was similar when comparing the results of treatment with anterior fusion with those of debridement.<sup>7,21-27</sup> This may be due to the instability being inadequately addressed by anterior surgery alone, although subsequent remodelling has been widely documented.<sup>1,3,4,6,7,10,15-17,19,21-29</sup> These considerations have led us to the understanding that various types of lesion require different surgical treatment. During the period of this study many patients were treated non-operatively and responded well to medical treatment. This group is not considered here.

Patients in group A had a lesion which involved only the anterior column. The disease was either of the classical paradiscal type or situated, less commonly, in the central body. Destruction in the latter lesion starts in the centre of the vertebral body and wedging is not pronounced although collapse of the body may occur later. The indications for surgical intervention in this group were spinal deformity ( $>30^\circ$ ), significant neurological deficit at presentation, failure of a non-operative trial of management for six to eight weeks, persistent severe pain, and neurological deficit which did not resolve or which developed while on medical treatment. These lesions are best treated surgically by anterior transthoracic fusion.<sup>5,30</sup> This approach leads the surgeon directly to the lesion and allows good visualisation. The kyphosis causes compression of the anterior column, and the graft is therefore also compressed.<sup>5</sup> When there is evidence of cord compression anterior decompression is also carried out.

In group B, both the anterior and posterior columns were compromised. Anterior lesions sometimes extended into the pedicles. These lesions were intrinsically unstable and required anterior and posterior stabilisation if correction of the deformity was to be maintained. In active lesions, correction of the deformity can easily be achieved by instrumentation of the posterior column using a closed-loop rectangle fixed by sublaminar wires.<sup>16,31</sup> The posterior elements provide a better purchase for implants than the diseased anterior column.<sup>15</sup> The posterior implant acts as a tension-band device. Vertebral bodies at the adjacent levels are hyperaemic and osteoporotic,<sup>28</sup> and anterior or pedicular instrumentation is therefore inappropriate. Although more levels are fused by the closed-loop rectangle, this does not cause functional restriction of movement in thoracic or thoracolumbar spines.

The initial posterior instrumentation 'opens' up the anterior lesion and allows correction of the deformity. Fusion of three levels on each side of the lesion provides the necessary long lever arm to obtain and maintain correction. In the initial cases we chose instrumentation alone. We found an early loss of correction and failure of the implant and therefore added an anterior bone graft. If the anterior procedure is carried out first, followed by posterior instrumentation, the graft may be unstable. Hence the anterior procedure follows the posterior procedure. A graft of an appropriate size replaces the deficiency in the anterior

column. The use of anterior grafts alone has not produced good results, particularly when more than two levels are involved.<sup>24</sup> The grafts assist in maintaining the contour of the spinal column.<sup>16</sup> If the graft is adequately protected by posterior instrumentation, a suitable biomechanical environment promotes fusion and progression of the deformity.<sup>24</sup>

Group C comprised patients with either anterior or global lesions who were at particular risk if subjected to transthoracic surgery. This may have been due to their age, associated medical conditions or poor respiratory function. In such cases the procedure was carried out entirely through the posterior approach. The cord was decompressed by excising a pedicle in order to allow access to the anterior debris. A limited debridement was undertaken to decompress the cord without creating a large defect. The exposure for the decompression may be improved by sacrificing a spinal nerve root at the level of the excised pedicle. This does not significantly affect the morbidity because of the overlap of the dermatomes and circumvents the problems related to a thoracotomy. The posterior instrumentation allows early mobilisation, thus avoiding the complications of prolonged recumbency.<sup>9</sup>

The transpedicular route for decompression is preferable to the transthoracic procedure<sup>9</sup> since it allows an adequate global removal of the anterior, lateral and posterior cuff of tissue, posterior stabilisation is possible through the same approach and chest complications related to thoracotomy in these patients are avoided.

Group D comprised patients with disease of the posterior column. Decompression was required, but not fusion. Decompression may be limited to a laminectomy or may be extended posterolaterally. The extent of the decompression is determined by the extent of local disease. Removal of facets from one side does not lead to instability since the anterior column is intact. We have not felt the need to fuse or to introduce instrumentation. Some lesions are granular and dry, forming a thick cuff around the cord. The cuff represents global compression even with an intact anterior column. Excising this tissue decompresses the cord.

Sublaminar wiring and the closed-loop rectangle have been the preferred implants in our series since they are cheap, easy to use and extra-osseous, whereas anterior or pedicular implants have poor fixation in osteoporotic bone near an infective focus. Although more segments are spanned in the thoracic spine, this does not limit movement as much as in the lumbar region.

The role of MRI in the diagnosis, classification, pre-operative planning and prognostic evaluation is presented. The classification is based on the site of the lesion, compression of the cord, instability, the extent of the deformity and patient-related factors. It is found to be useful in planning surgery for these complex problems.

No benefits in any form have been received or will be received from a commercial party related directly or indirectly to the subject of this article.

## References

1. Altman GT, Altman DT, Frankovitch KF. Anterior and posterior fusion for children with tuberculosis of the spine. *Clin Orthop* 1996;325:225-31.
2. Reichman LB. Tuberculosis elimination: what's to stop us? *Int J Tuberc Lung Dis* 1997;1:3-11.
3. Tuli SM. *Tuberculosis of the skeletal system: bones, joints, spine and bursal sheaths*. 2nd edition, Bangalore, etc:Jaypee Brothers 1997.
4. Chen W-J, Chen C-H, Shih C-H. Surgical treatment of tuberculous spondylitis: 50 patients followed for 2-8 years. *Acta Orthop Scand* 1995;66:137-42.
5. Hodgson AR, Stock FE. Anterior spine fusion for the treatment of tuberculosis of the spine. *J Bone Joint Surg [Am]* 1960;42-A:295-310.
6. Medical Research Council Working Party on Tuberculosis of the Spine. Five year assessments of controlled trials of ambulatory treatment, debridement and anterior spinal fusion in the management of tuberculosis of the spine: studies in Bulawayo (Rhodesia) and in Hong Kong. *J Bone Joint Surg [Br]* 1978;60-B:163-77.
7. Medical Research Council Working Party on Tuberculosis of the Spine. A controlled trial of anterior spinal fusion and debridement in the surgical management of tuberculosis of the spine in patients on standard chemotherapy: a study in Hong Kong. *Br J Surg* 1974;61:853-66.
8. Paus B. The changed pattern of bone and joint tuberculosis in Norway. *Acta Orthop Scand* 1977;48:277-9.
9. Bhojraj SY, Dandawate AV, Ramakantan R. Preoperative embolisation, transpedicular decompression and posterior stabilisation for metastatic disease of the thoracic spine causing paraplegia. *Paraplegia* 1992;30:292-9.
10. Boachie-Adjei O, Squillante RG. Tuberculosis of the spine. *Orthop Clin North Am* 1996;27:95-103.
11. Jain R, Sawhney S, Berry M. Computed tomography of vertebral tuberculosis: patterns of bone destruction. *Clin Radiol* 1993;47:196-9.
12. Kim NH, Lee HM, Suh JS. Magnetic resonance imaging for the diagnosis of tuberculous spondylitis. *Spine* 1994;19:2451-5.
13. Naim-Ur-Rahman, Jamjoom A, Jamjoom ZA, Al-Tahan AM. Neural arch tuberculosis: radiological features and their correlation with surgical findings. *Br J Neurosurg* 1997;11:32-8.
14. Nussbaum ES, Rockswold GL, Bergman TA, Erickson DL, Seljeskog EL. Spinal tuberculosis: a diagnostic and management challenge. *J Neurosurg* 1995;83:243-7.
15. Guven O, Kumano K, Yalcin S, Karahan M, Tsuji S. A single stage posterior approach and rigid fixation for preventing kyphosis in the treatment of spinal tuberculosis. *Spine* 1994;19:1039-43.
16. Moon MS, Woo YK, Lee KS, et al. Posterior instrumentation and anterior interbody fusion for tuberculous kyphosis of dorsal and lumbar spines. *Spine* 1995;20:1910-6.
17. Moon MS, Ha KY, Sun SH, et al. Pott's paraplegia: 67 cases. *Clin Orthop* 1996;323:122-8.
18. Rajasekaran S. Prediction of the angle of gibbus deformity in tuberculosis of the spine. *J Bone Joint Surg [Am]* 1987;69-A:503-9.
19. Schulitz K-P, Kothe R, Leong JCY, Wehling P. Growth changes of solidly fused kyphotic bloc after surgery for tuberculosis: comparison of four procedures. *Spine* 1997;22:1150-5.
20. Shipley JA, Craig JB. Spinal tuberculosis with translational instability. *Spine* 1993;18:397-401.
21. Travlos J, duToit G. Spinal tuberculosis: beware of the posterior elements. *J Bone Joint Surg [Br]* 1990;72-B:722-3.
22. Tuli SM. Severe kyphotic deformity in tuberculosis of the spine. *Int Orthop* 1995;19:327-31.
23. Medical Research Council Working Party on Tuberculosis of the Spine. A 10-year assessment of a controlled trial comparing debridement and anterior spinal fusion in the management of tuberculosis of the spine in patients on standard chemotherapy in Hong Kong. *J Bone Joint Surg [Br]* 1982;64-B:393-8.
24. Rajasekaran S, Soundarapandian S. Progression of kyphosis in tuberculosis of the spine treated by anterior arthrodesis. *J Bone Joint Surg [Am]* 1989;71-A:1314-23.

25. Upadhyay SS, Sell P, Saji MJ, Sell B, Hsu LCS. Surgical management of spinal tuberculosis in adults: Hong Kong operation compared with debridement surgery for short and long term outcome of deformity. *Clin Orthop* 1994;302:173-82.
26. Upadhyay SS, Saji MJ, Sell P, Sell B, Hsu LCS. Spinal deformity after childhood surgery for tuberculosis of the spine: a comparison of radical surgery and debridement. *J Bone Joint Surg [Br]* 1994; 76-B:91-8.
27. Upadhyay SS, Sell P, Saji MJ, et al. 17-year prospective study of surgical management of spinal tuberculosis in children: Hong Kong operation compared with debridement surgery for short- and long-term outcome of deformity. *Spine* 1993;18:1704-11.
28. Medical Research Council Working Party on Tuberculosis of the Spine. A 10-year assessment of controlled trials of in-patient and out-patient treatment and of Plaster-of-Paris jackets for tuberculosis of the spine in children on standard chemotherapy: studies in Masan and Pusan, Korea. *J Bone Joint Surg [Br]* 1985;67-B:103-12.
29. Upadhyay SS, Sell P, Saji MJ, Leong JCY. Radical and debridement surgery for tuberculosis of the spine in children: a preliminary analysis of results from a 17-year prospective study. *Eur Spine J* 1994;1:231-5.
30. Hsu LCS, Cheng CL, Leong JCY. Pott's paraplegia of late onset: the cause of compression and results after anterior decompression. *J Bone Joint Surg [Br]* 1988;70-B:534-8.
31. Dove J. Luque segmental spinal instrumentation: the use of the Hartshill rectangle. *Orthopedics* 1987;10:955-61.